

Minimally invasive and patient-friendly treatment concepts using one-piece implants

Renaissance of One-Piece Implants

Hannes Thurm-Meyer, dentist, Bremen, Germany,
Thomas Horn, master dental technician, Hamburg, Germany and
Sebastian Brahman, master dental technician, Hamburg, Germany

Efficient, safe and simple treatment methods in oral implantology have been in demand as never before. Following this trend, we have been observing a renaissance of one-piece implants. These implants permit minimally invasive surgical techniques, maximum tissue preservation, a simpler treatment sequence and lower cost. The present article describes a patient receiving a removable telescopic bridge using zirconia primary crowns and electroplated secondary copings. The copings were adhesively connected to a tertiary framework in situ, allowing a passive and accurate fit of the superstructure.

One-piece implants are currently experiencing a renaissance in implant dentistry – for a variety of reasons, the most important of which are minimally invasive surgical techniques, maximum tissue preservation, a simpler treatment sequence and lower cost. In terms of implant prosthodontics, technical complexity is minimized by reducing the number of components required, which also means that less treatment time is required. In conjunction with state-of-the-art CAD/CAM technologies, numerous innovative treatment options are now available, encompassing the entire range of modern prosthodontics. Linking natural teeth and dental implants using zirconia primary crowns and electroplating technology makes for aesthetic removable bridge designs. The following case report presents a patient treated with FairOne (FairImplant) implants, which are characterized by an anti-rotational design of the prefabricated implant head and a root-shaped conical osseous aspect. The design of the implant head allows prosthetic treatment without additional preparation effort.

Case report

Clinical baseline situation

The 61-year-old patient had been treated for her chronic periodontitis for more than 15 years (Fig. 1) and had received multiple surgical and conservative periodontological treatments during that time (Fig. 2). The patient requested a comprehensive maxillary and

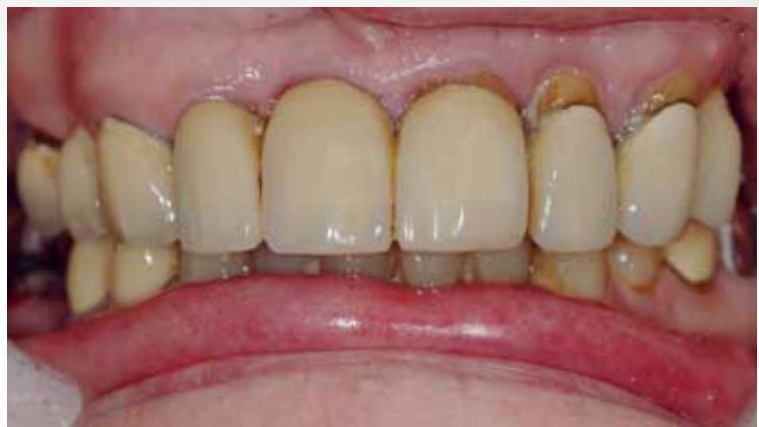

Fig. 1 Periodontally compromised baseline situation.

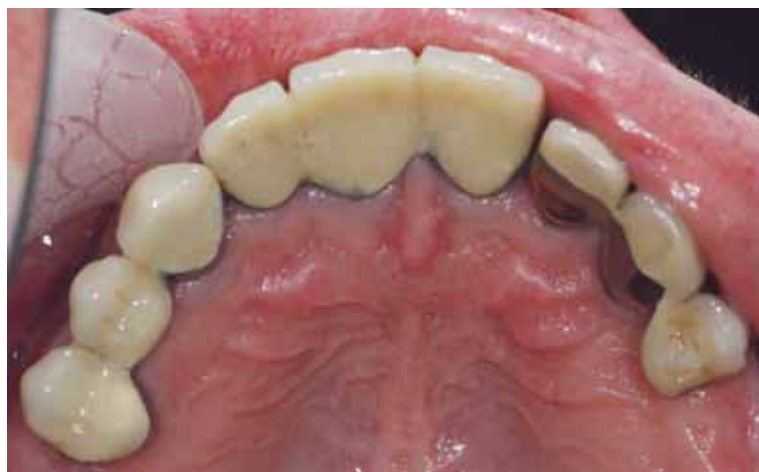

Fig. 2 Insufficient restorations.

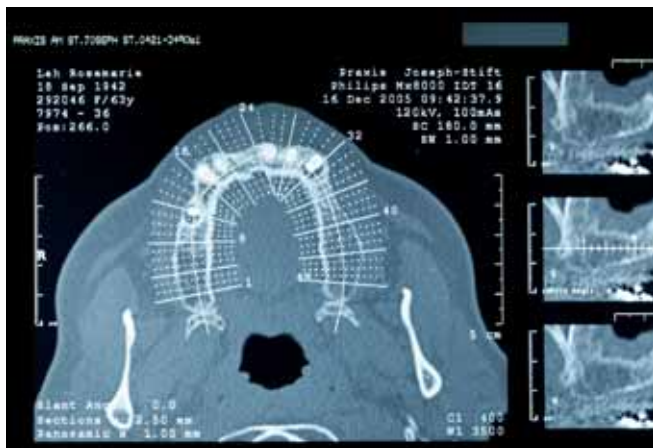

Fig. 3 CT scan.

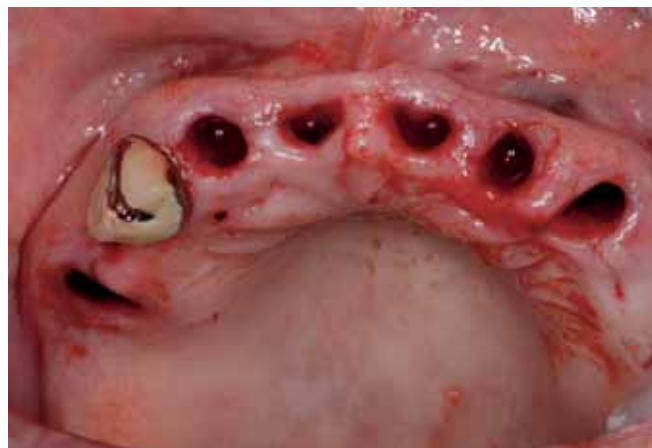


Fig. 4 Surgical situation following multiple extractions.

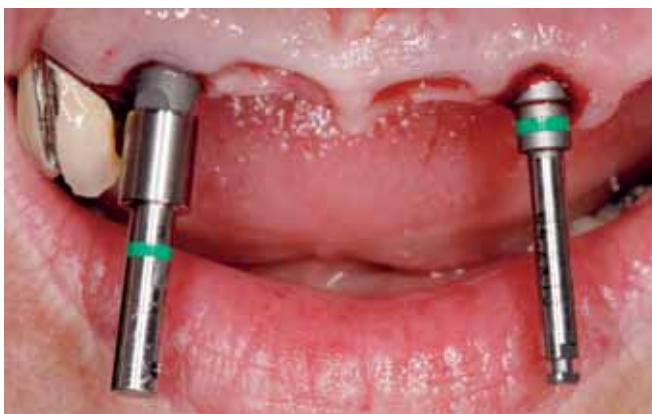

Fig. 5 Immediate implant insertion at sites 12 and 22.

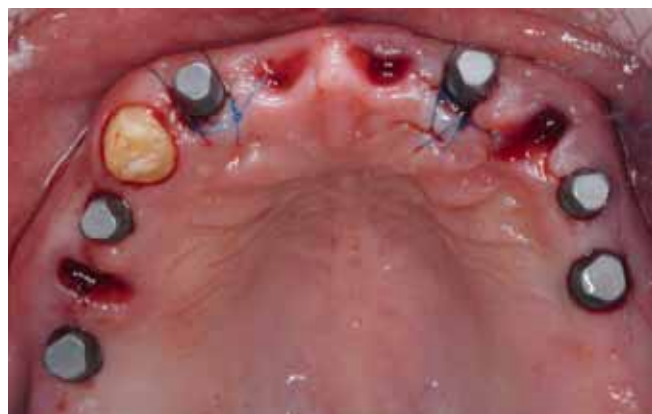

Fig. 6 Immediate implant insertion at sites 12, 22. Minimally invasive implant insertion at sites 16, 14, 24 and 25.

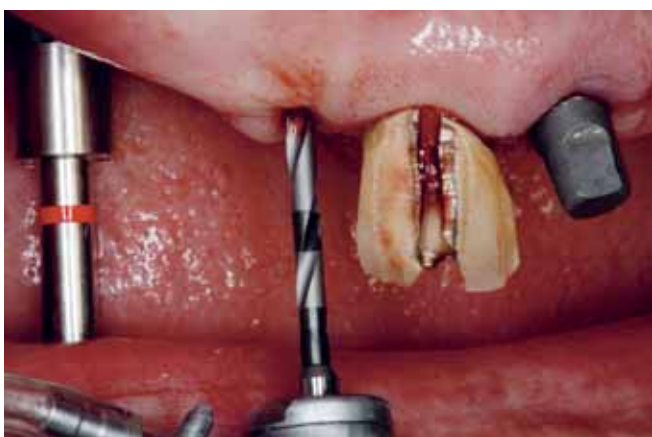

Fig. 7 Implant insertion at sites 16, 14, 24 and 26.

mandibular rehabilitation. Because the patient exhibited a pronounced retching urge, a solution involving a fixed restoration or a removable restoration without palatal coverage had to be found. In addition, the mandible was to be restored, to the extent possible, with fixed crowns and bridges following the completion of the periodontal therapy.

Diagnosics and treatment planning

In addition to the usual general, periodontological, functional and radiological diagnostic procedures, a CT scan was performed to allow a more comprehensive evaluation (Fig. 3). The abutments were carefully selected, and the treatment plan for the maxilla was defined as follows: Extraction of the hopeless teeth 15, 12, 11, 21, 22 and 23 (Fig. 4), insertion of one-piece implants, with a roughened surface throughout, at sites 16, 14, 12, 22, 24 and 25 (Fig. 5 and 6) and insertion of a removable telescopic bridge using zirconia primary crowns and electroplated secondary copings.

Implant placement

Implants 16, 14, 24 and 25 were inserted using a minimally invasive surgical procedure, including mucosal punching (Fig. 7). An internal sinus floor elevation was performed at sites 16 and 25, while immediate implant insertion was performed at sites 12 and 22. All implants exhibited primary stability at torques of 40 and 45 Ncm. Vertical interrupted sutures were used to adapt the soft tissues. A drilling stent was employed for all primary drilling.

Following successful implant insertion, a previously fabricated immediate denture without palatal coverage was inserted using a soft silicone liner. Wound healing progressed without any complications and with minimal pain (Fig. 8). Particularly impressive was the adaptation of the soft tissues one week postoperatively. The subsequent healing process was also free of complications. At implant site 16, a superficial gingivitis was found after a longer control interval, which receded quickly and had presumably been caused by irritation from the immediate denture. Implant integration of the soft and hard tissues progressed without irritation. Peri-implant probing depths were between 1 and 2 mm.

In our experience, this type of result is commonly observed with one-piece implants. It may well represent a promising approach – toward improvements in the soft-tissue integration of dental implants, toward elimination or at least reduction of bone remodelling and toward better preservation of the sensitive and aesthetically important structures in the emergence zone.

Preparation

An impression was taken and a diagnostic cast poured to check the path of insertion of the implants and to make any adjustments necessary. To transfer the situation to the patient, preparation aids made of pattern resin were provided to the dentist, who then proceeded to cutting back the problematic areas and to optimizing the one-piece titanium implants, following the preparation guidelines for all-ceramic primary telescopes. Provided that suitable instruments are used and the dentist has a bit of practice, preparing titanium implants is no more difficult than preparing teeth.

The prefabricated heads of the implants used are characterized by three flanges, greatly simplifying the preparation effort and ensuring rotational stabil-

ity. This stability is retained after preparation, since the original head still defines the basic shape of the preparation. Placing one of the available flat surfaces vestibularly when inserting the implant is a good idea. If a chamfer has been provided for a subgingival crown margin, a primary retraction cord is placed to protect the gingiva and to indicate biologic width prior to preparation. Size 000 non-impregnated retraction cord is used and remains in place for the impression (Fig. 9). Using the Zekyra retractor (Malleffer) for gingival protection has often proven valuable. During preparation, this retractor was guided parallel to the grinding bur. Used in conjunction with the retraction cord, the instrument protected the gingiva from trauma, effectively barring titanium chips from intruding. Standard techniques were used to take the impression. The arbitrary hinge axis was transferred to the articulator using a facebow, and the master casts were poured (Fig. 10).

The first bite registration – centric registration using a unique pink and aluminium wax registrate – was taken in a separate session. We decided that the

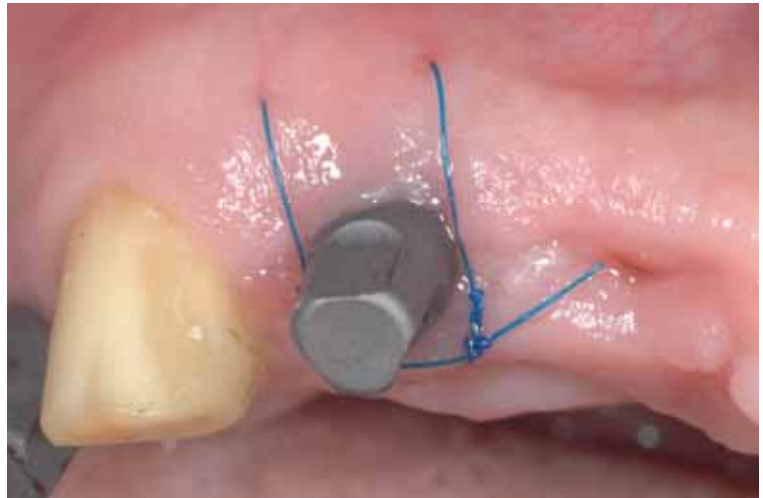


Fig. 8 One week postoperatively – non-irritant soft-tissue healing.

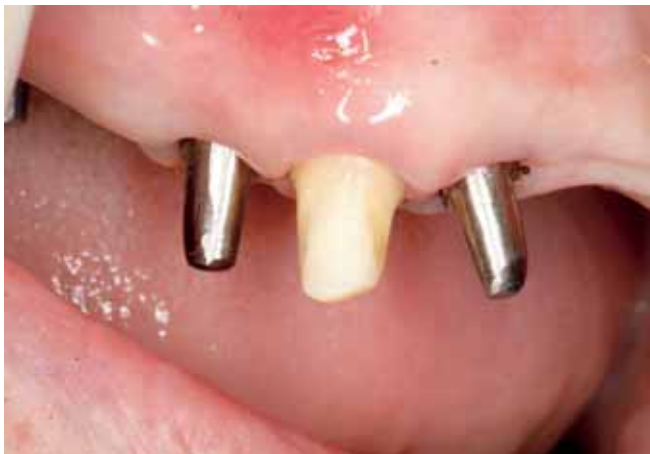

Fig. 9 Four months postoperatively.

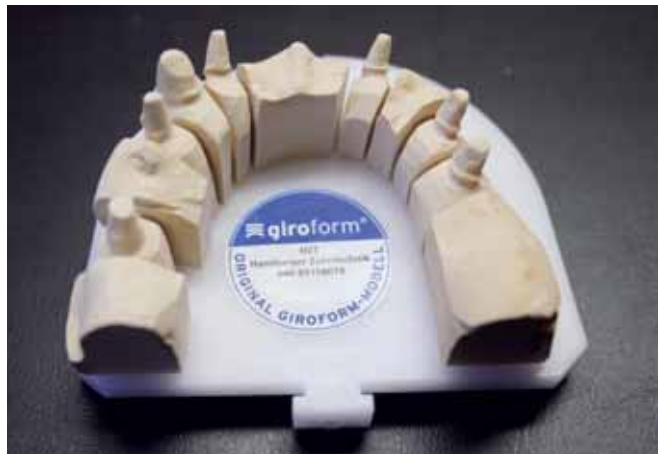

Fig. 10 Saw-cut model with excellently prepared dies.

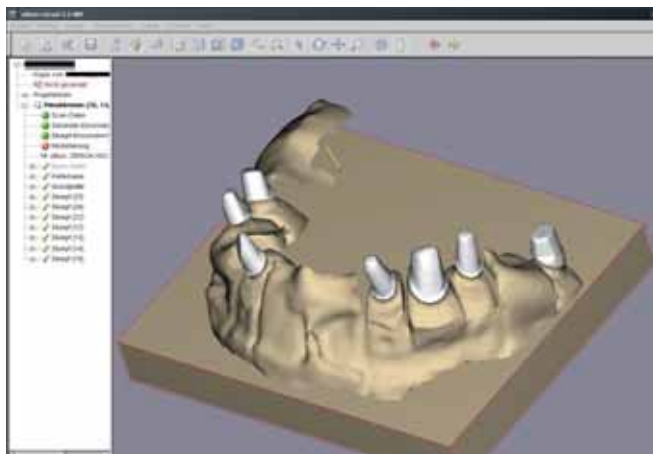


Fig. 11 The virtual cast (etkon CAD system).

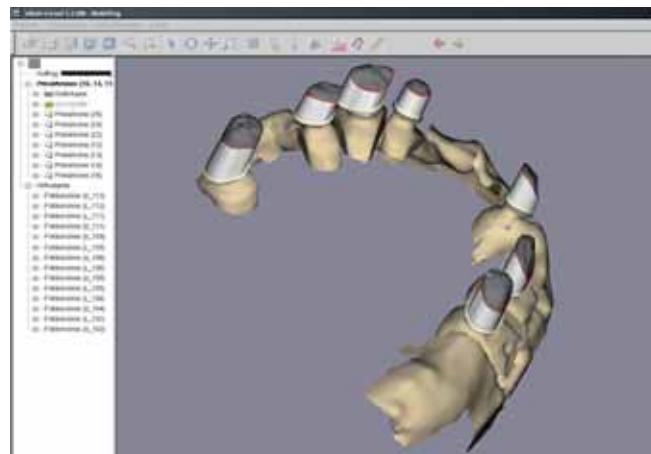


Fig. 12 Virtual wax-up of the primary crowns on the screen.



Fig. 13 Electroplated copings on the cast.

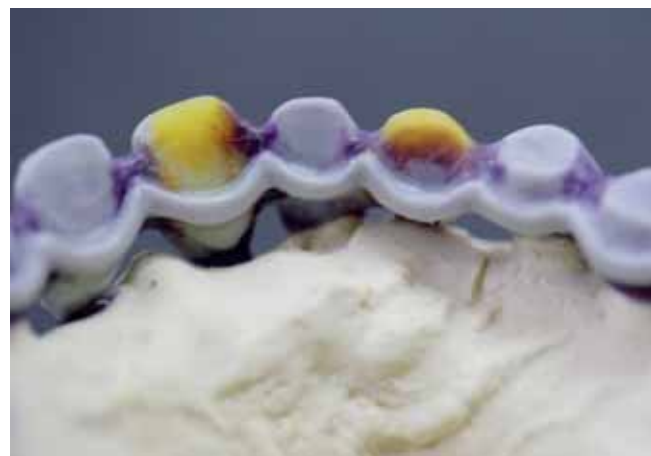

Fig. 14 Waxing up the tertiary framework.

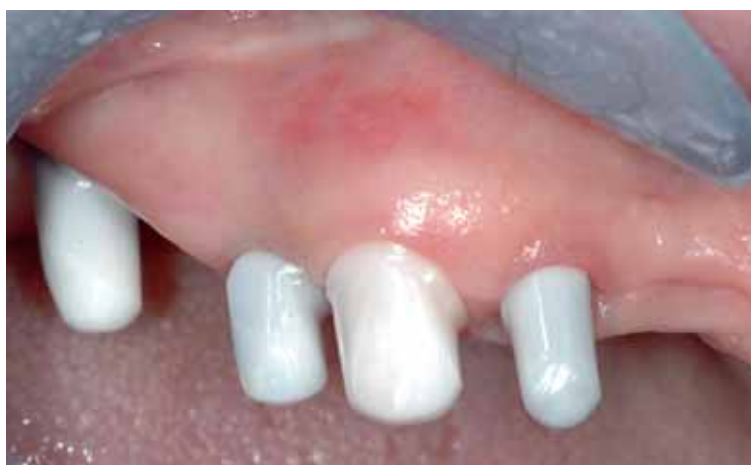

Fig. 15
The primary telescopes for 16, 14, 13 and 12 cemented in place.

necessary precision of the bite registration could be achieved only by dispensing with local anaesthesia and by directly checking the fit on the master casts. The vertical dimension of occlusion had been documented at the outset, defined by the intraoral distance of the deepest points of the gingival scallops of teeth 13 and 43. This value had already been transferred to the cast and elevated by 1.5 mm when the

immediate provisional denture had been fabricated. Since the provisional denture had been worn for a protracted period without complications, it could be assumed that the craniomandibular system had completely adapted to this vertical dimension.

Prosthesis

It is at this point that the dental technician realizes the benefits of working with one-piece implants, as the subsequent laboratory procedures are both uncomplicated and cost-effective. The dies were prepared and scanned as usual (Fig. 11). Taking the available vertical space into account, the etkon visual telescope software was used to create the primary telescopes in an 80 percent automated process (Fig. 12), which were then tried on, finished and electroplated (Fig. 13). A tertiary framework was modeled above the zirconia/electroplated telescopes and cast, then finished and prepared for a more detailed bite registration (Fig. 14).

This was followed by a try-in of the primary crowns (Fig. 15), the electroplated secondary copings and the tertiary structure, and subsequently by cementing,

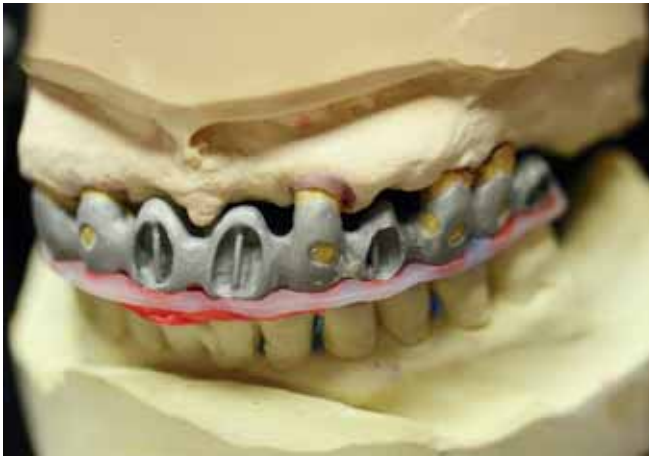
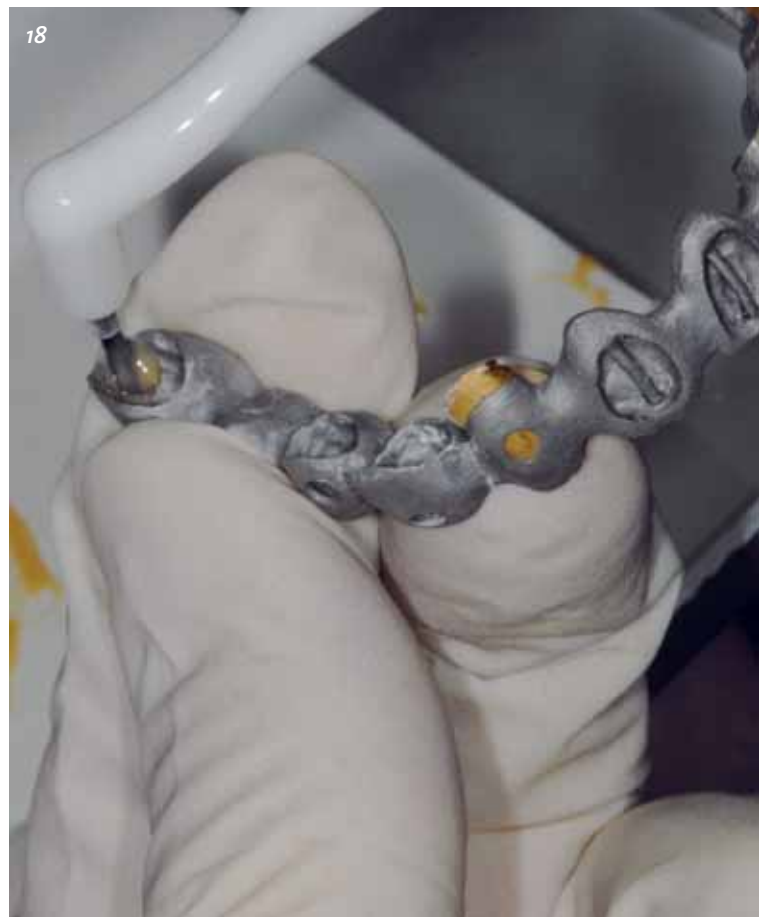
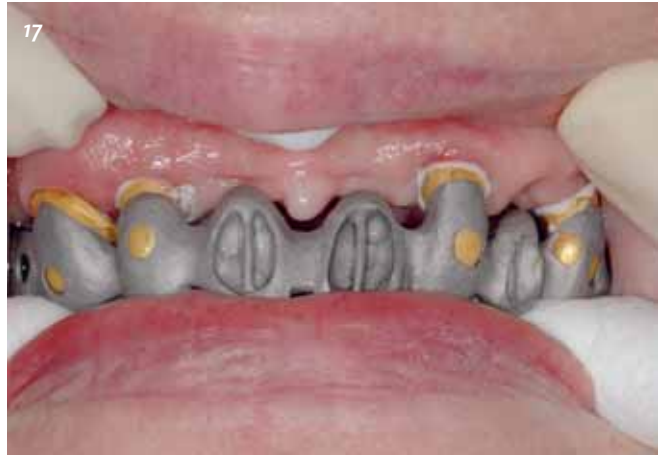
Fig. 16 The master casts were placed in the articulator based on the arbitrary hinge axis.



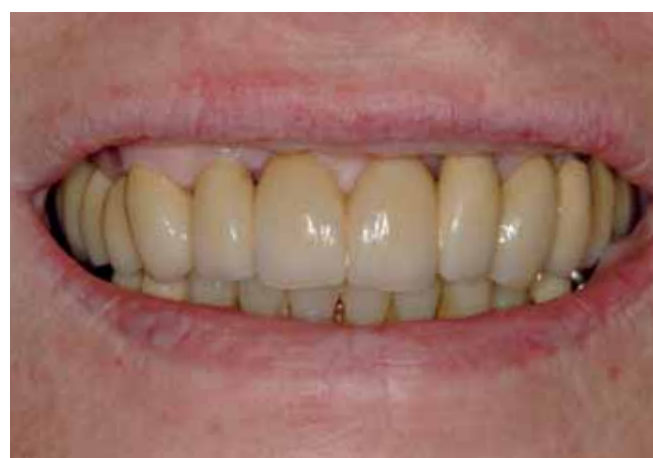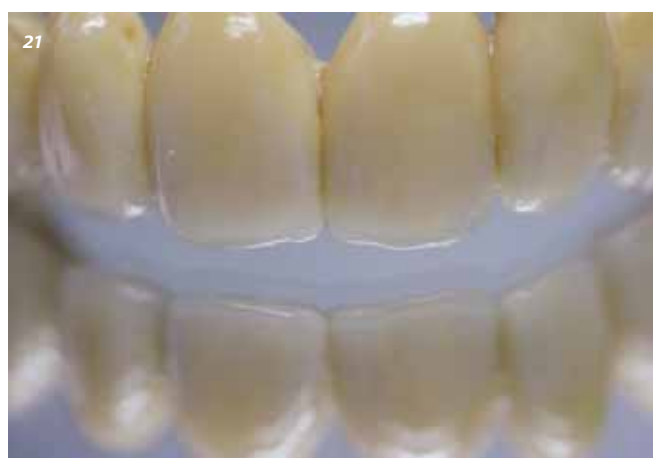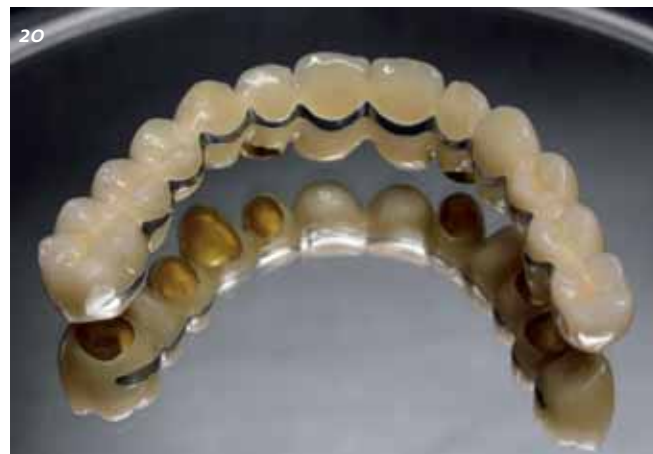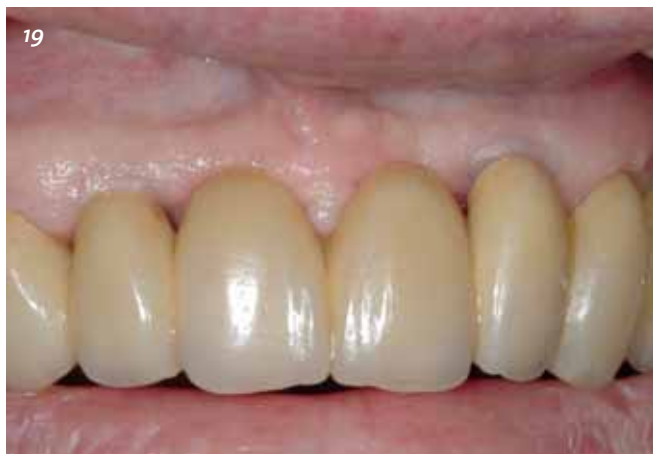Figs. 17 and 18 Trial insertion of the tertiary framework and adhesive connection of the secondary copings to the tertiary framework.

intraoral adhesive connection and a definitive bite registration (Figs. 16 to 18). A custom resin tray was used for taking an overimpression and registering the soft-tissue structures. The patient's existing temporary denture, which she continued to wear during the healing phase, was slightly relieved around the primary telescopes, then relined and fitted above the zirconia primary crowns as a so-called travel denture. This denture will be used by the patient as a replacement restoration while her definitive restoration is cleaned or repaired. At the laboratory, the electroplated copings were provided with resin dies, and the master cast was poured and placed in the articulator.

The subsequent veneering step was initiated by a "coarse" dentine layer, with various effects added one by one for individual characterization, so that the resulting shade was in no way second to the natural teeth (Figs. 19 to 21). The removable telescopic bridge was inserted without problems. It required no adjustment thanks to the passive and accurate, uniformly frictional fit, precise bite registration, custom aesthetic veneers and an anatomic design of the occlusal surfaces (Fig. 22). The slight irritation of the mucosa caused by the provisional restoration receded after only a few days.

Conclusions

The patient's acceptance of the treatment plan and restorative solution were certainly promoted by the use of one-piece titanium implants with a roughened surface through out, careful treatment planning



Figs. 19 to 21 Details after four months in situ: composite veneers and custom characterization.

Fig. 22 Final restoration in situ.

Contact Address

Hans Thurm-Meyer & Partner

Joint specialist practice for
periodontology, functional diagnostics,
implantology and endodontology

Richtepad 4
28355 Bremen
GERMANY

ZTM Thomas Horns

HZT Hamburger Zahntechnik oHG

Beselerstraße 24a
22607 Hamburg
GERMANY

and a minimally invasive insertion technique. It was gratifying to see how seamlessly the soft tissues adapted to this implant type, especially in the case of the immediate implants at sites 12 and 22. We presume that this was owed to the fact that single-piece implants exhibit no microcracks between implant body and abutment and that the implant type used had a rough surface throughout. The implant technique depended on the presence of sufficient tissue dimensions and on primary stability being achieved safely. With the introduction of the zirconia/electroplating technique, the double-crown approach has been improved to the point where natural abutments and implants can be routinely used as mixed support for removable restorations exhibiting a passive and accurate fit. ■

